spontaneous coronary artery dissections

SCAD



@hartvoorvrouwen
www.hartvoorvrouwen.nl
FMD dag 25-11-2017
scad.cardio@radboudumc.nl

Radboud Women's Heart Center

Mw A, 41 jaar , geb 1975,

ACS (non-STEMI): SCAD- LAD , geen interventie

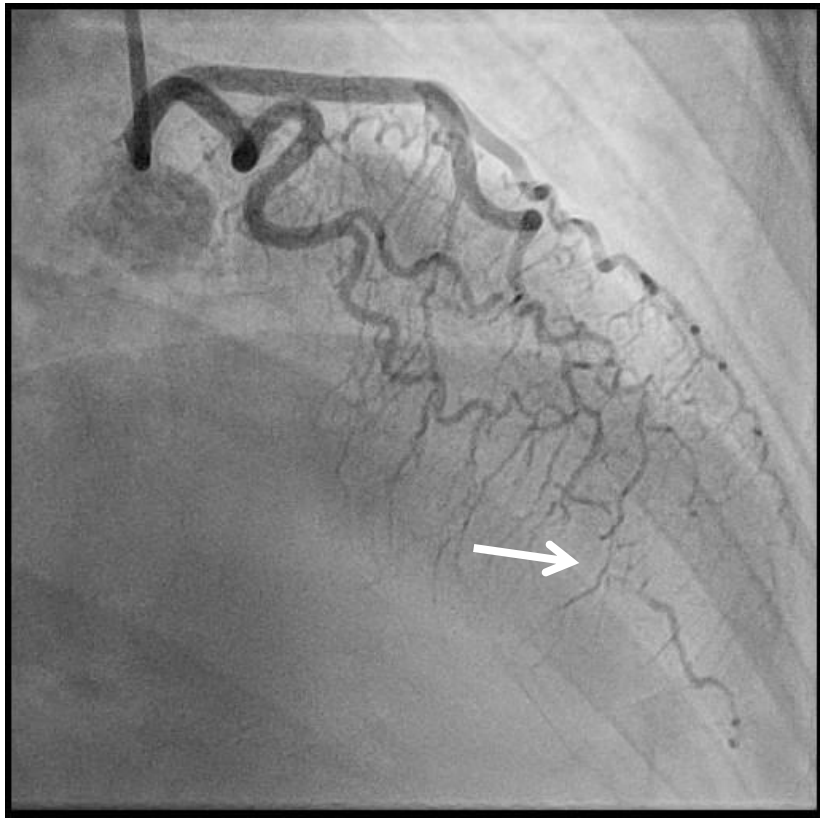

Mw B, 46 jr met SCAD distale LAD, bekend met FMD

Na PCI met plaatsing 4 stents LAD

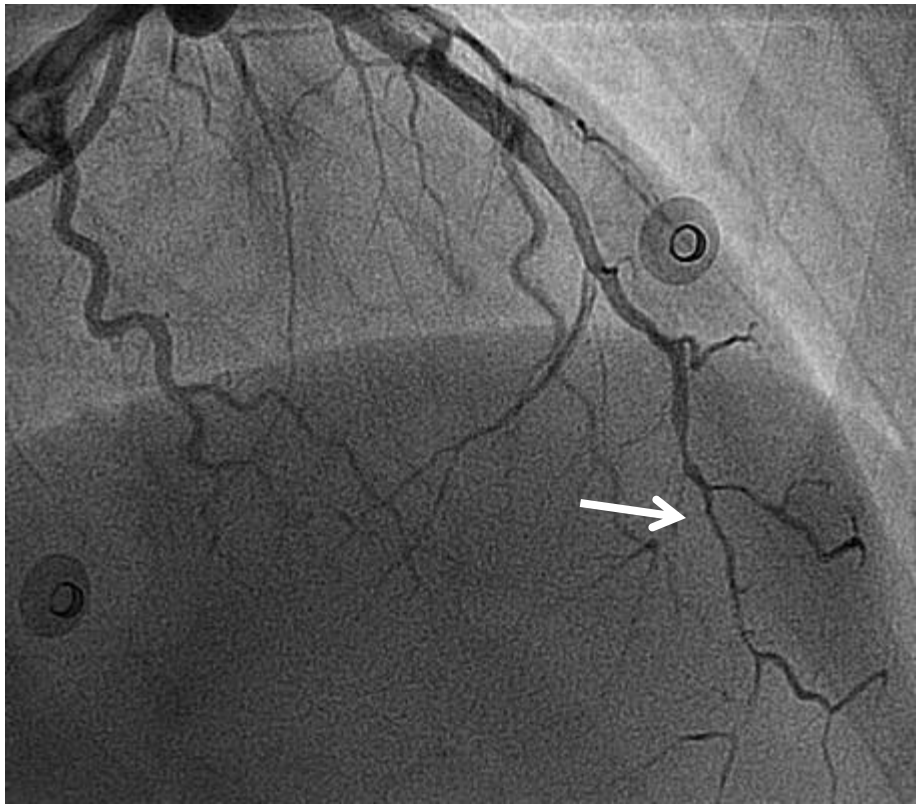

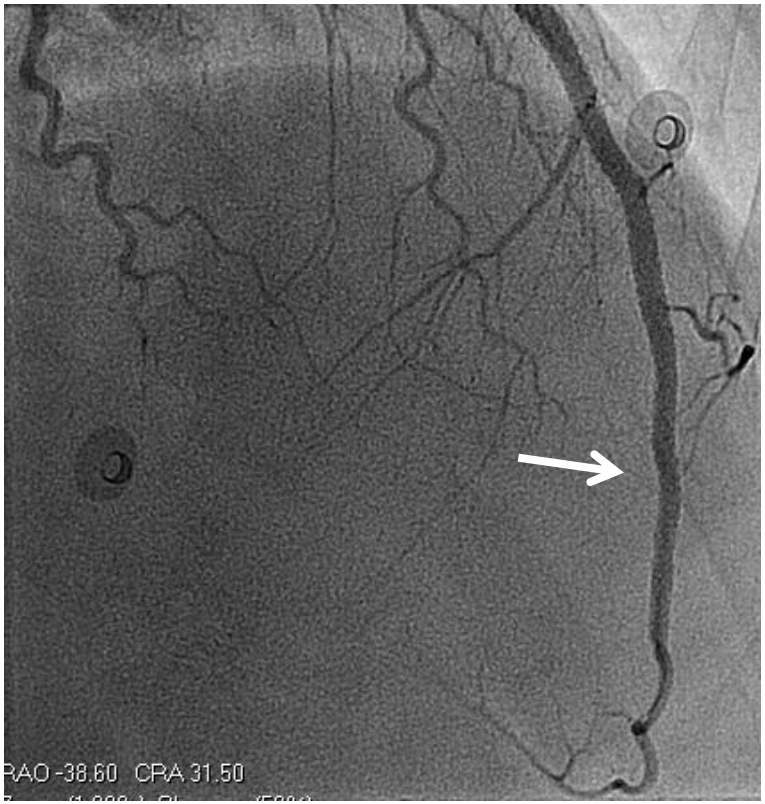

Pat C: SCAD, geen dotter, CAG na 6 maanden

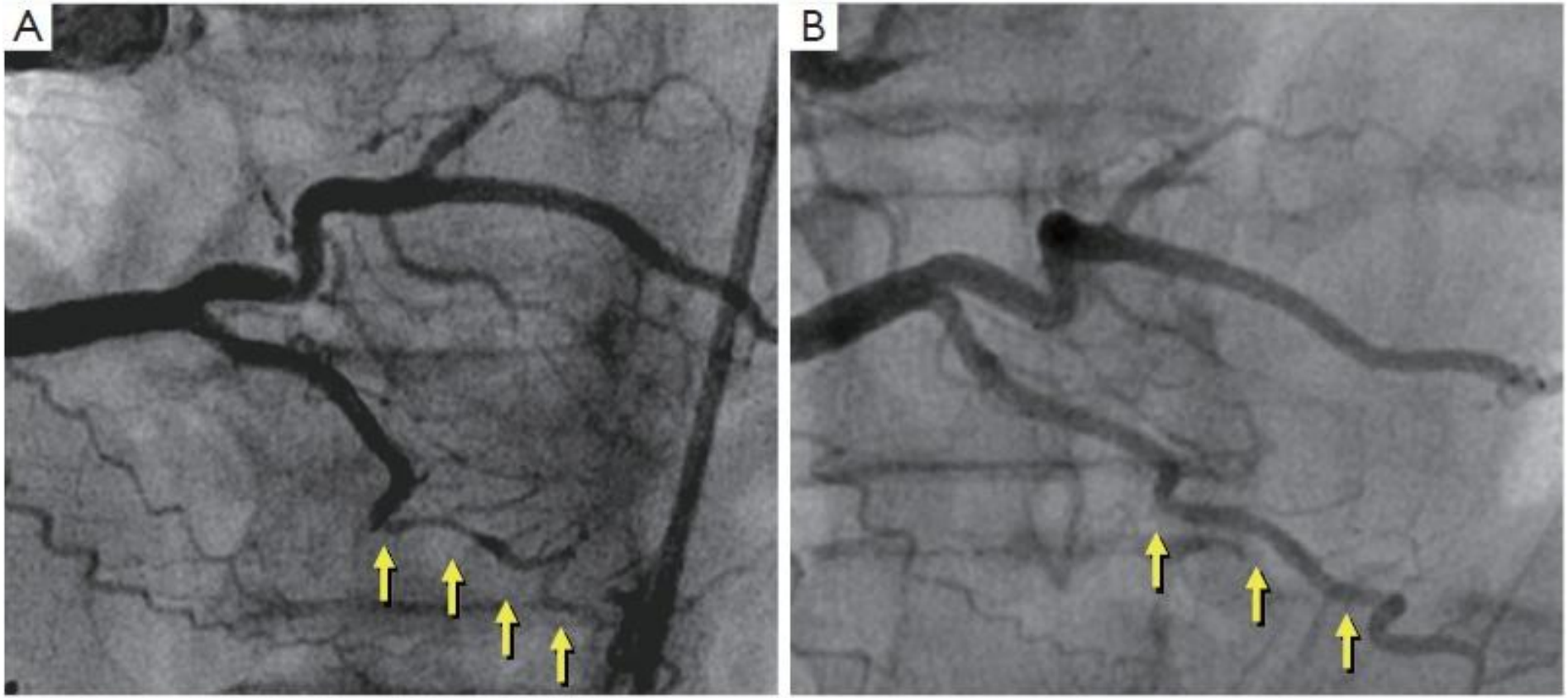

Alfonso F et al. Cardiovasc Diagnosis Ther 2015

Sex-specific aspects of ACS

Thrombus formation on a ruptured or eroded plaque

Classic type I ACS

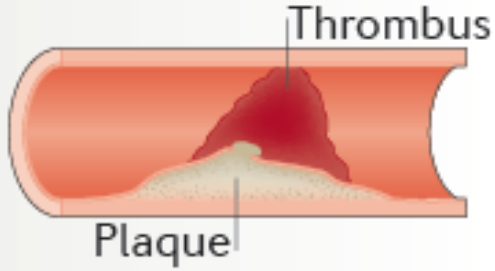

Coronary vasospasm

Type II ACS

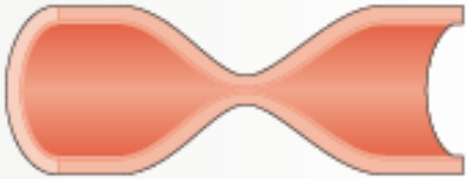

Spontaneous coronary artery dissection

SCAD: >> 90 % women
25% FMD

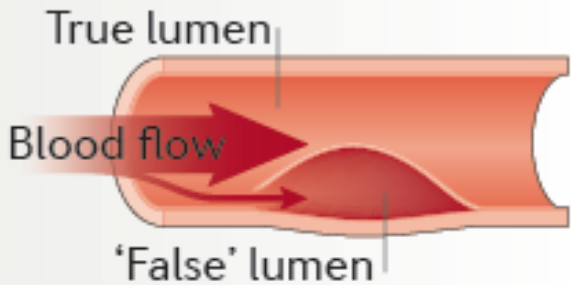

Stress-related (Takotsubo) cardiomyopathy

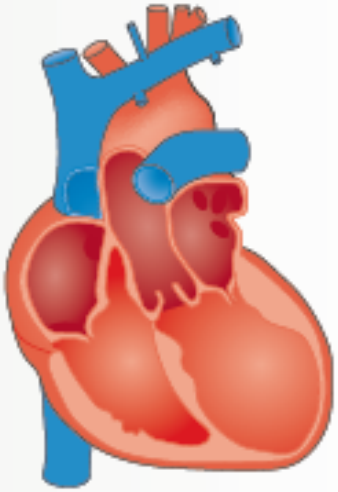

Note: chronic TTC-variants in PTSS

Blank spots in guidelines & lack of 'gender-balance'

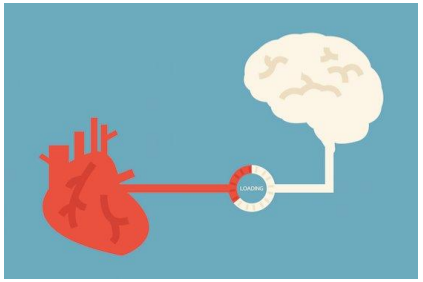

SCAD:



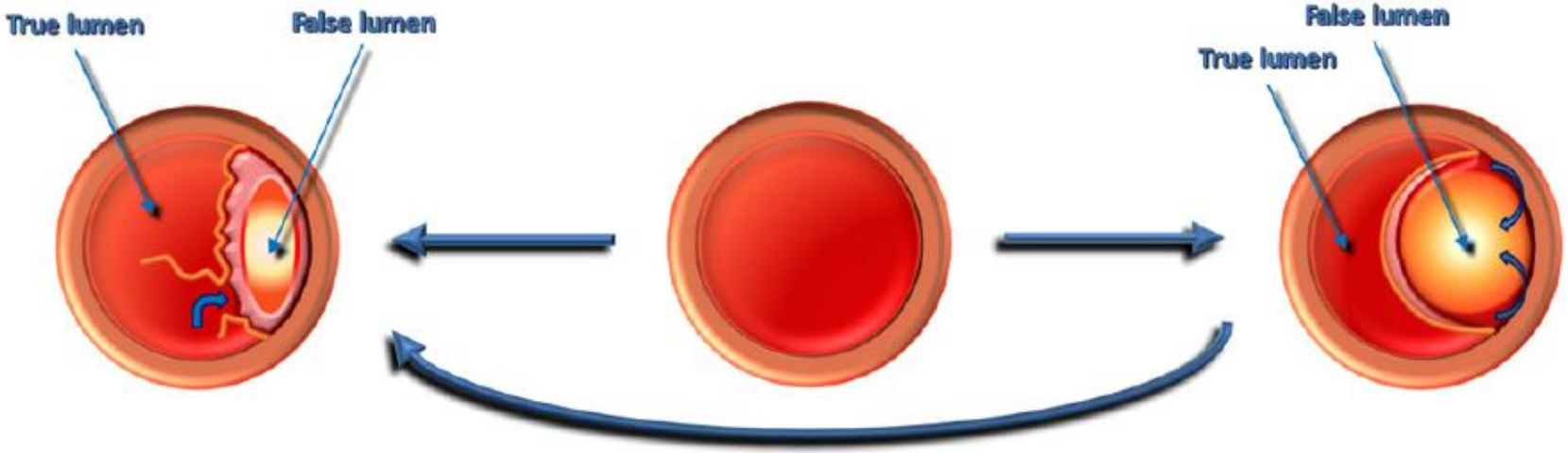

SCAD with entry door

SCAD without entry door

Angiographic classification SCAD

20% ACS in women < 60 years = SCAD (>50% LAD)

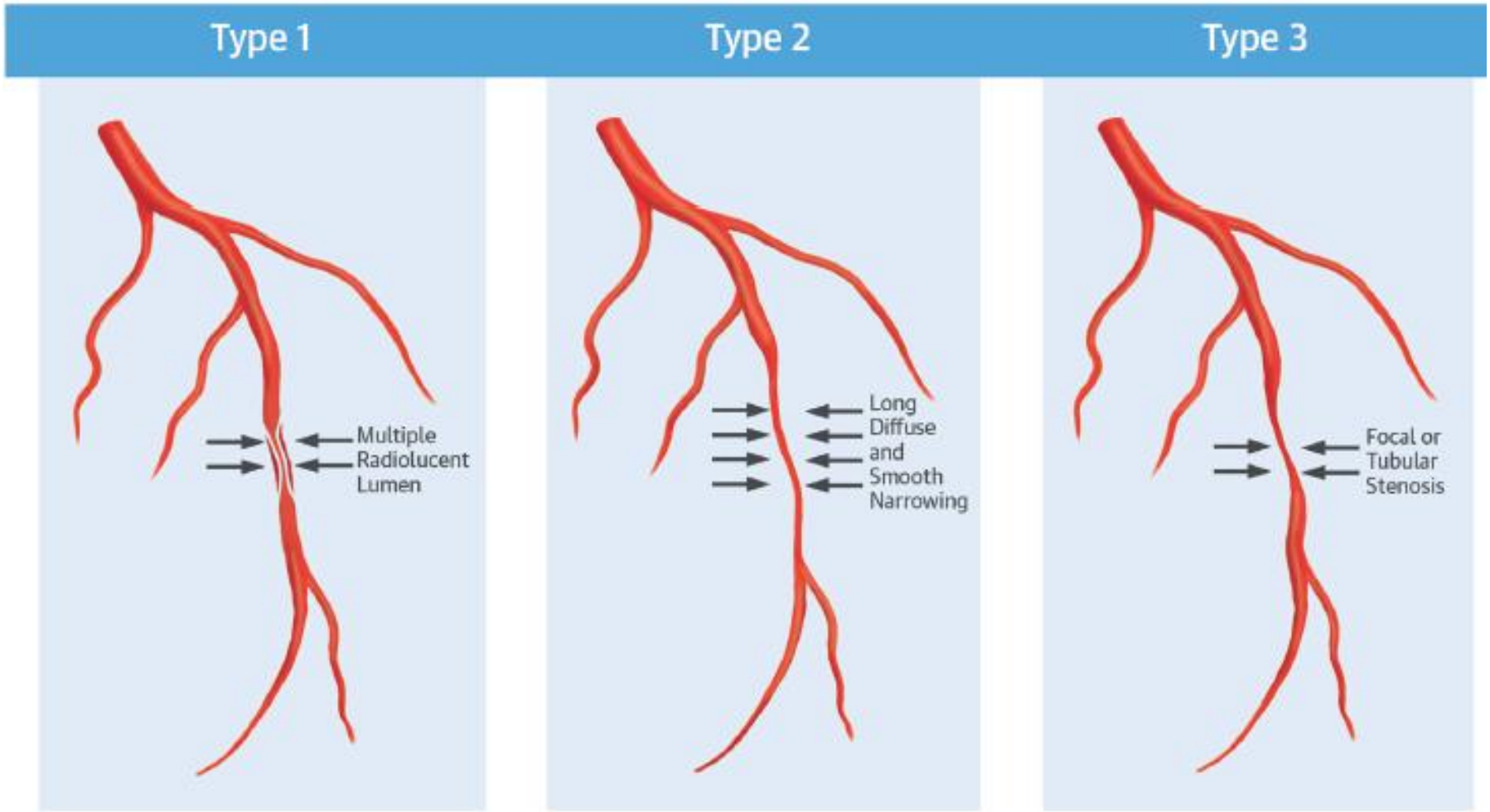

Saw J et al. JACC 2017

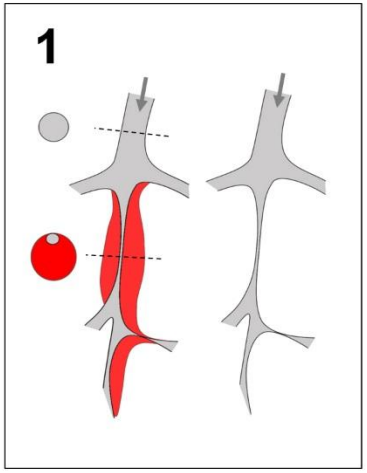

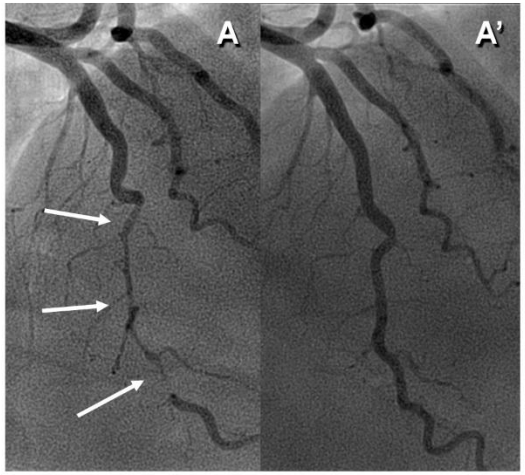

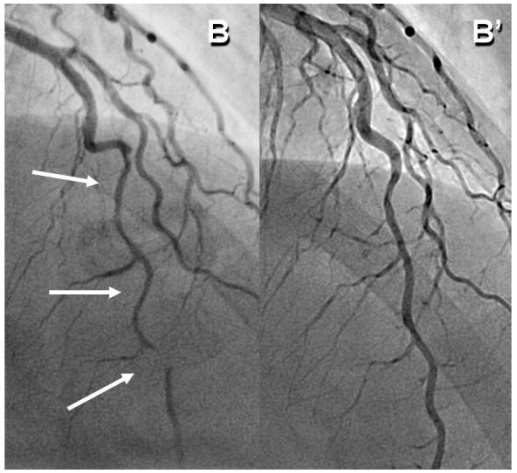

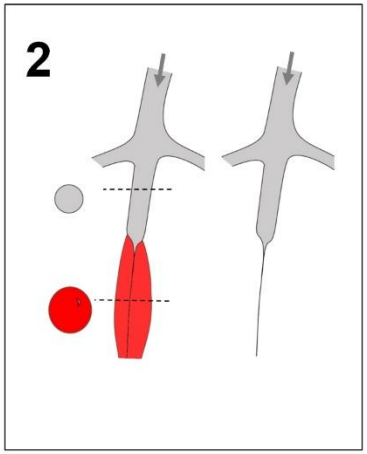

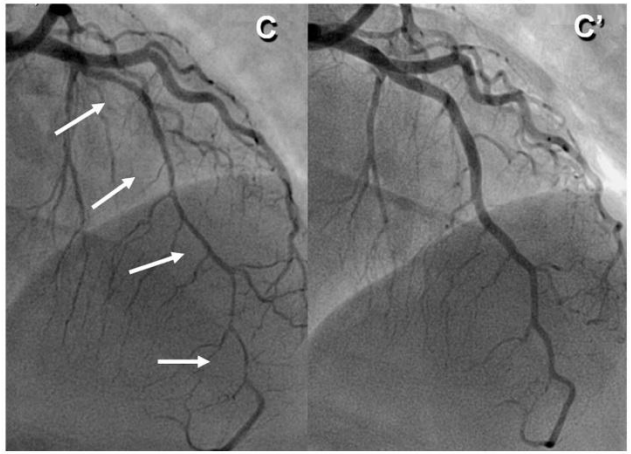

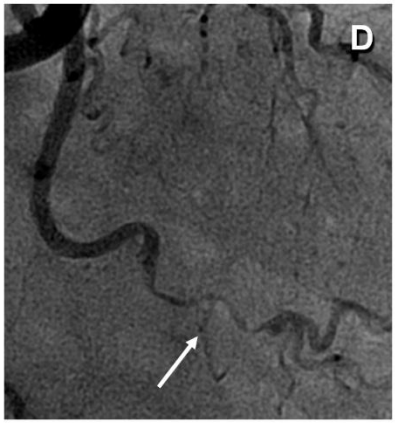

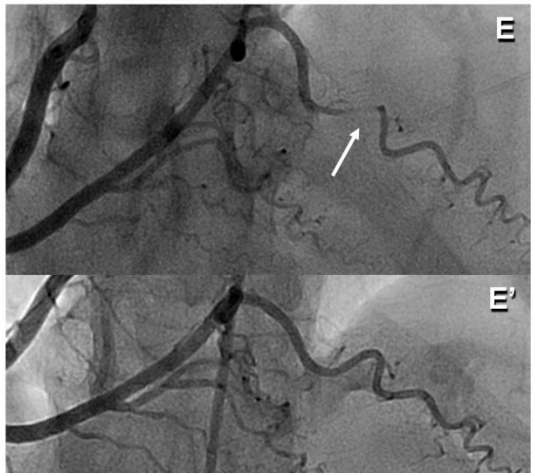

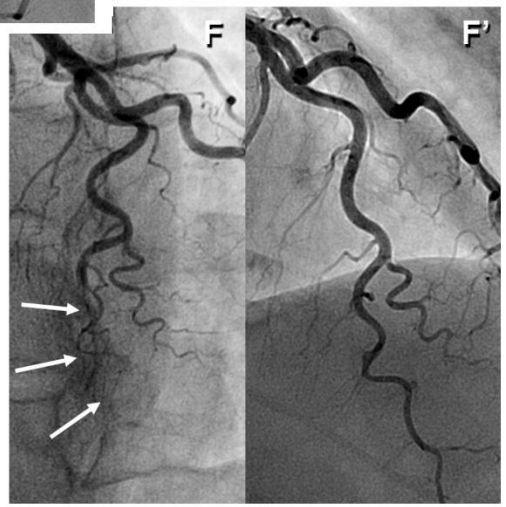

umc

Imaging in patients with SCAD:

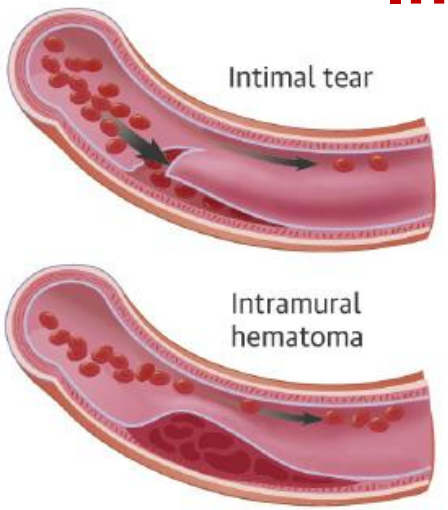

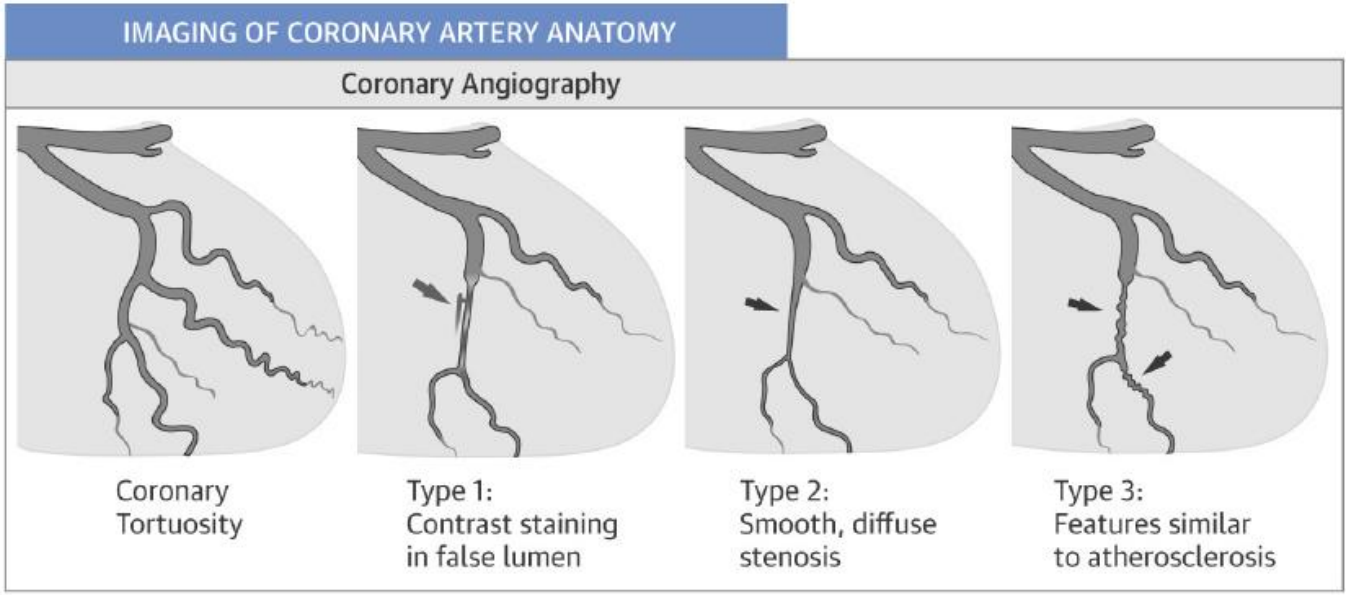

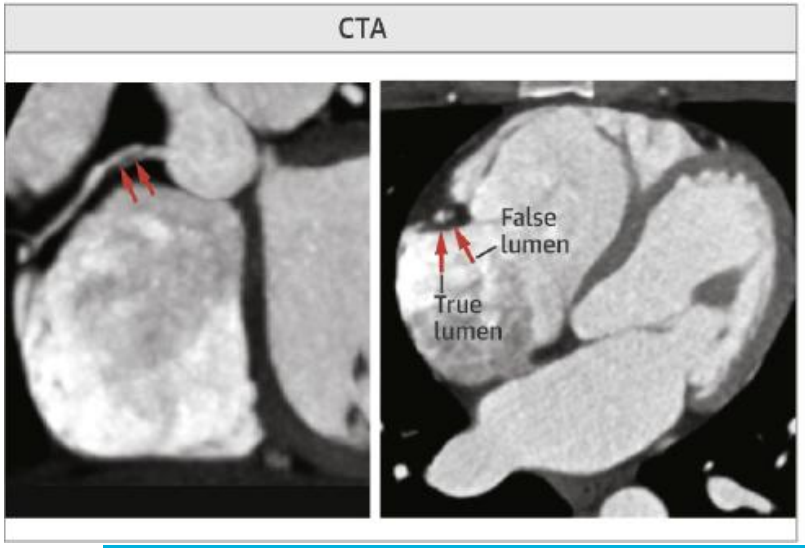

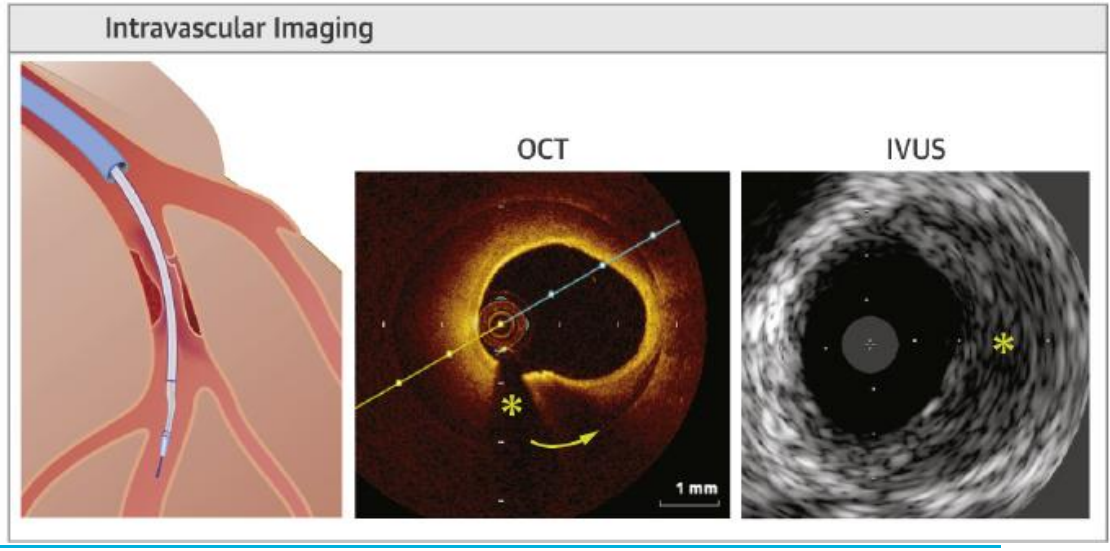

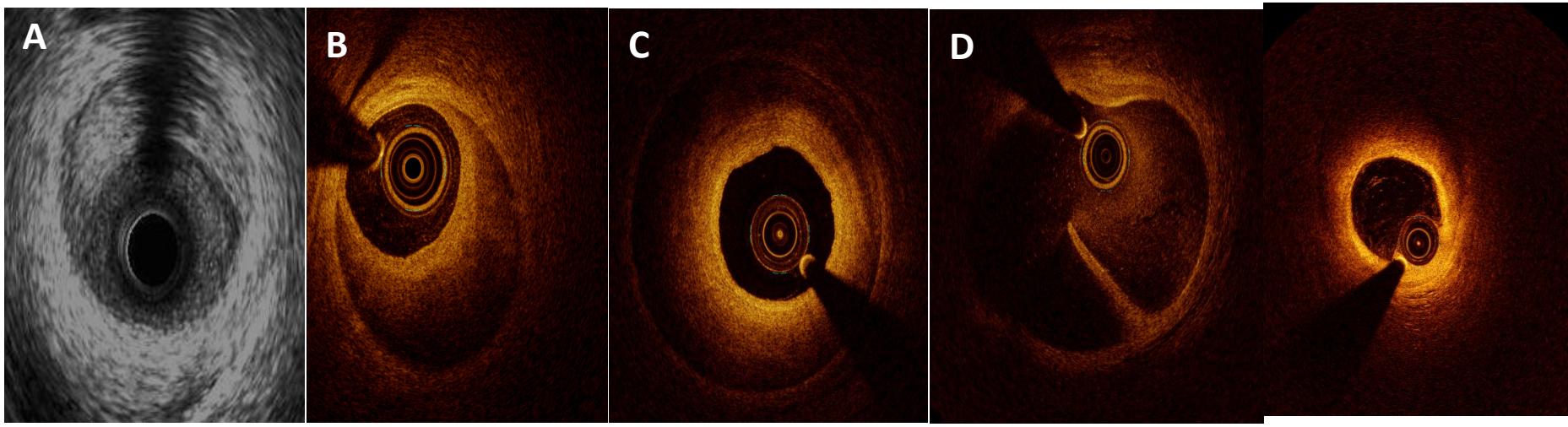
A
B
C
D



Leeftijdsverdeling SCAD (>> 90% vrouwen)

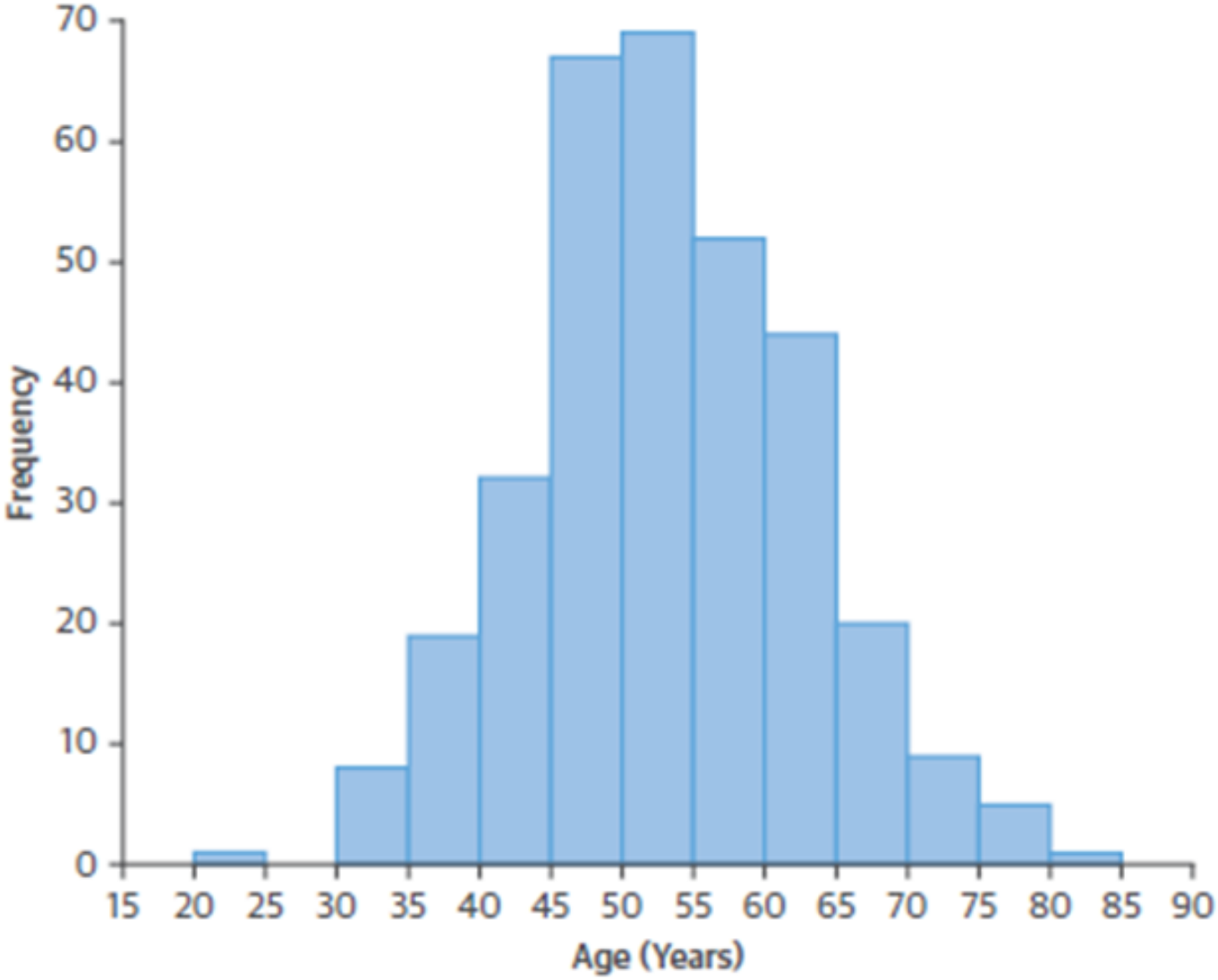

Saw J et al. JACC 2017

Leeftijdsverdeling SCAD (>> 90% vrouwen)

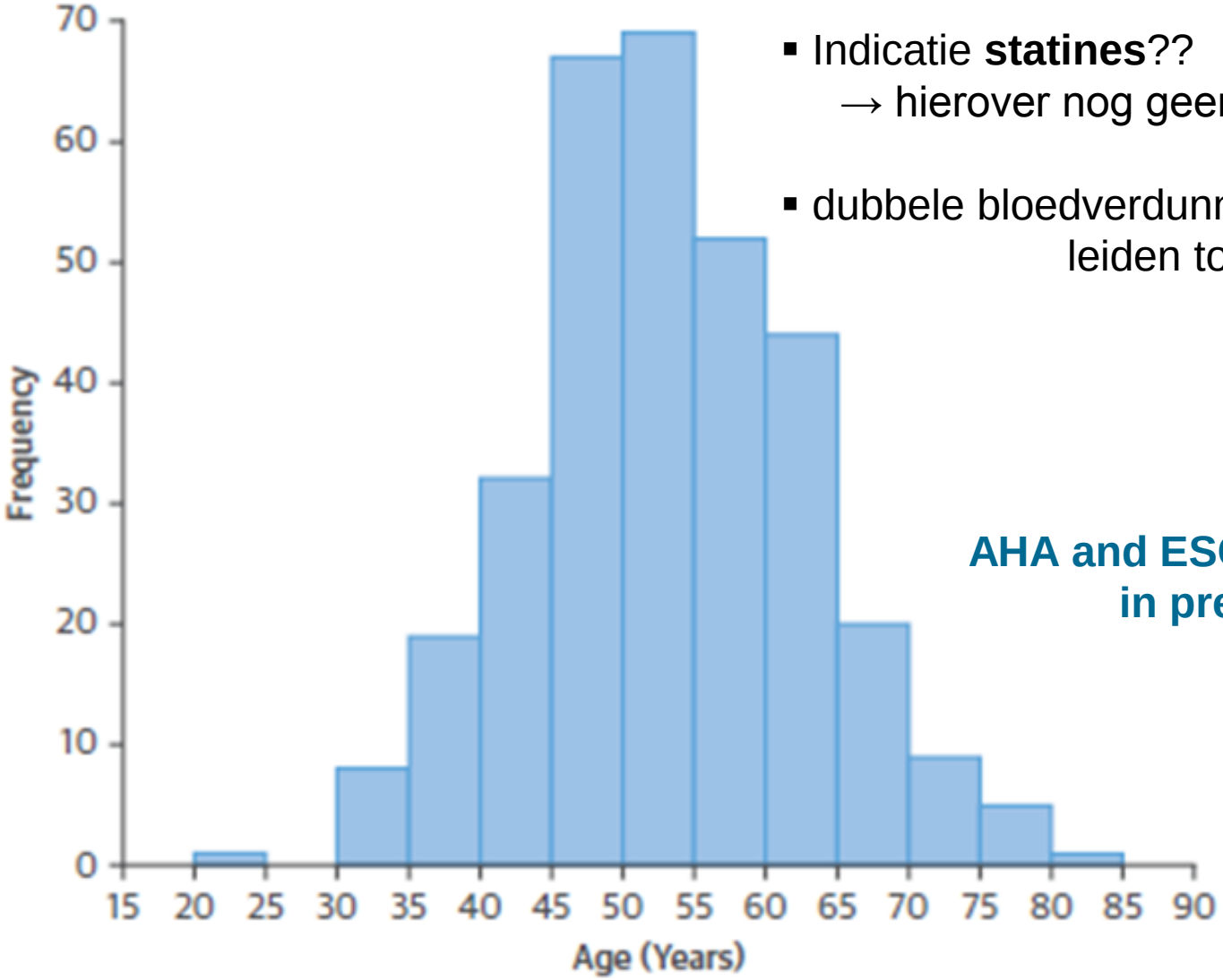

- Indicatie **statines**??
  → hierover nog geen richtlijnen SCAD
- dubbele bloedverdunners (**DAPT)** kunnen leiden tot hevige menstruatie

AHA and ESC position paper in preparation

Saw J et al. JACC 2017

SCAD: uitlokkende gebeurtenissen, oa

- **hoge bloeddruk**
- **zeer intensieve inspanning bv krachttraining**
- **intense plotse/langdurige emotionele stress**
- **bevalling (8%)**
- **extreem hoesten, kuchen**
- **gebruik cocaine, migrainemiddelen etc**

Kans op herhaling: 10-17%

Saw J et al. JACC 2016

Herhaalkans SCAD groter bij veel tortuositas ??

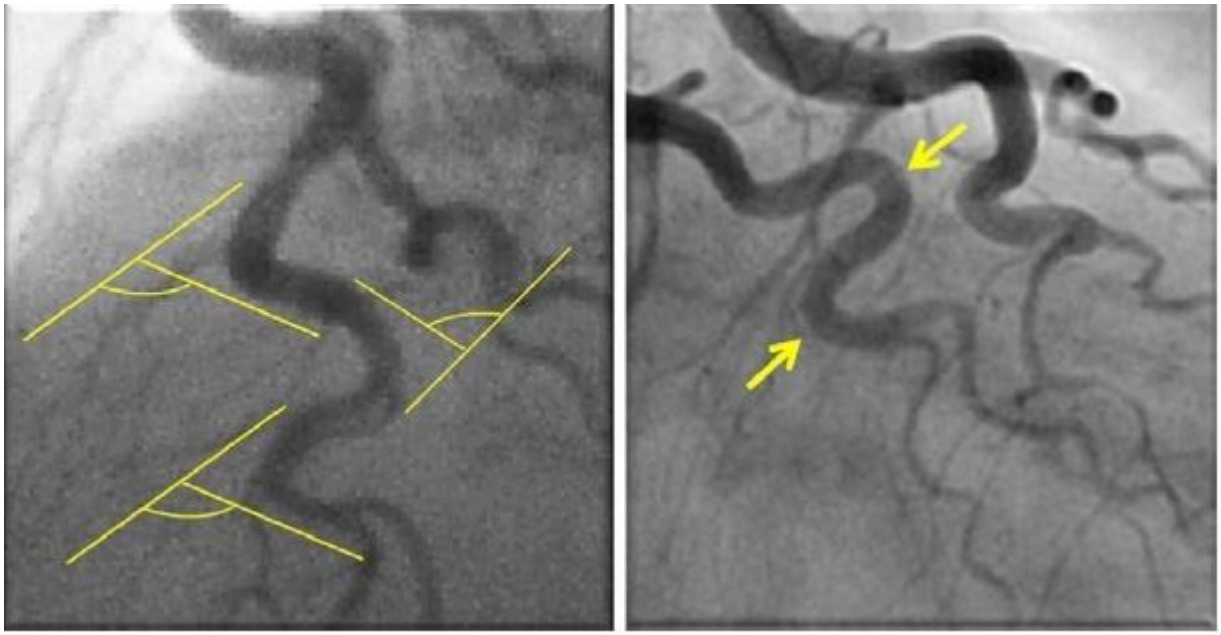

Eleid MF et al. Circ Cardiovasc Interv 2014; 7: 656-2.

Radboudumc

angiografische manifestaties FMD in de kransvaten:

> 90% vrouwen

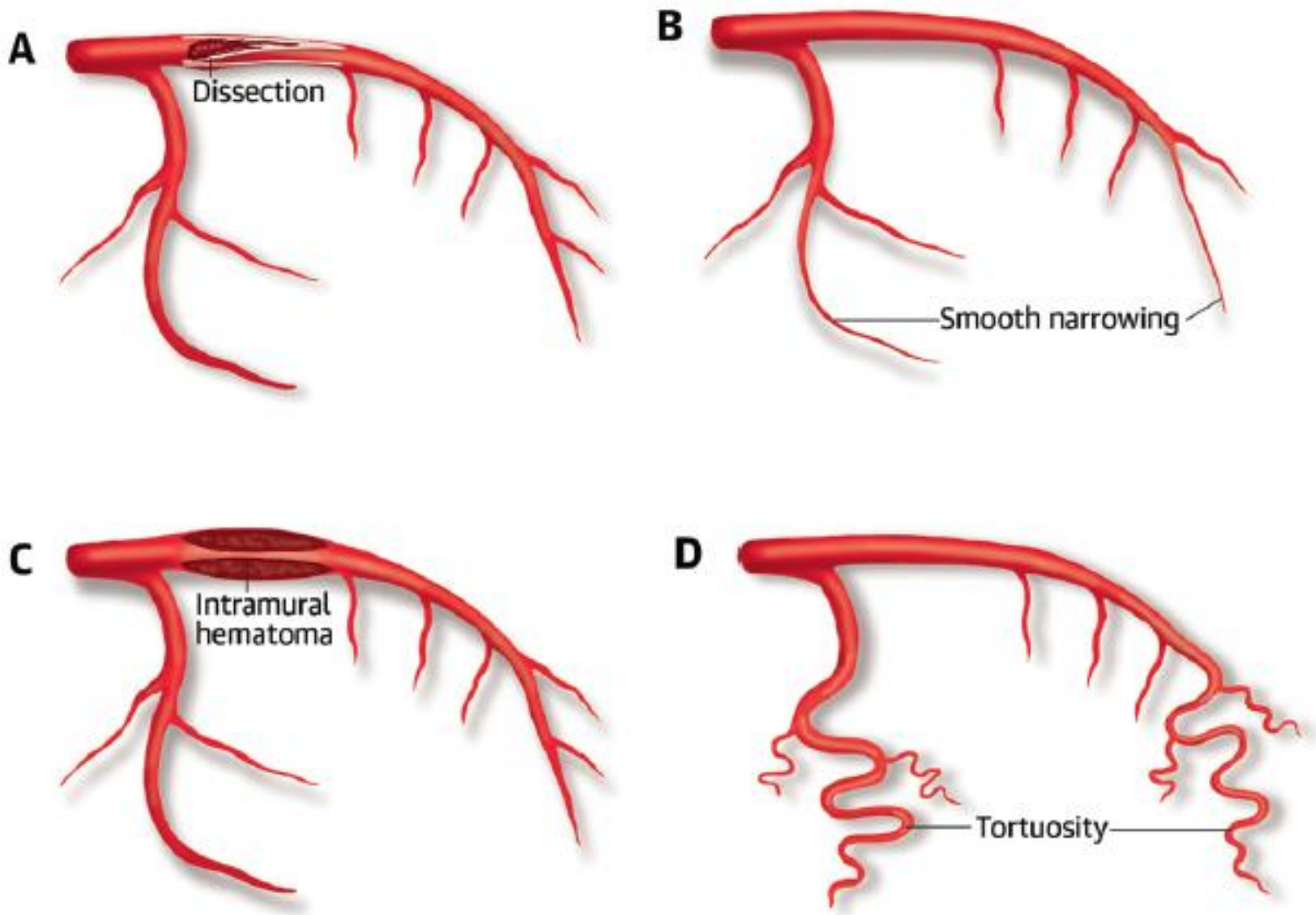

Michelis KC et al. J Am Coll Cardiol 2014; 64: 1033-46.

Behandeling SCAD:

NB recent scientific statement AHA, *no* *evidence-based* advise yet

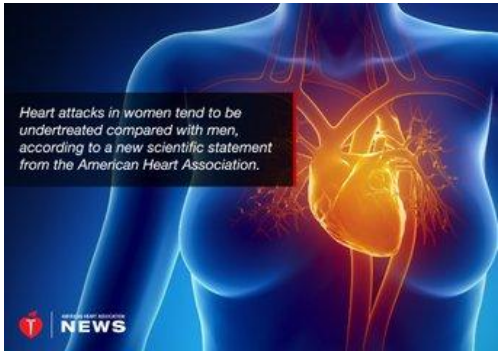

Mehta et al, Circulation 2016

Acute fase: - herstel doorbloeding kransvat
- minderheid PCI (en stent)

Herstel:

- hartrevalidatie
- genetica (mn bij hypermobiliteit, 5-7% afw.)
- beeldvorming (CT, MRI) nierarteriën (FMD)
- liever geen zwangerschap meer

- **Medicatie**: statines niet bewezen zinvol
  Acetylsalicylzuur (hoe lang?)
  behandel hoge bloeddruk (< 130/80)

- **Restklachten** (spasme): nitraten, calcium inhibitors (diltiazem)
  geen anticonceptiepil, evt Mirena

Tweet, MS et al. Mayo Clin Proceedings 2015

Radboudumc

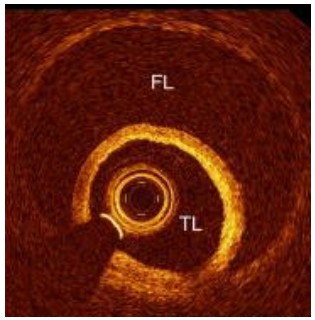

ESC-ACCA European Study Group on Spontaneous Coronary Artery Dissection

EUROPEAN SOCIETY OF CARDIOLOGY®

Dave Adlam, Fernando Alfonso, Angela Maas, Christiaan Vrints

Acute Cardiovascu
Care Associat
ACCA
A Registered Branch of th

The inaugural ESC-ACCA Spontaneous Coronary Artery Dissection Study Group breakfast meeting, at the ESC-Congress in Rome

Euro-Observational Research Program: EORP

- Begrijpen en evalueren van **huidige praktijkvoering** en **patientencategoriëen** in de cardiologische zorg voor SCAD (+FMD)

- Maken en Implementeren van **ESC richtlijnen** en samenstellen **onderwijs-programma** om kennis beter te verspreiden

- Formeren van expert-**referentie** centra

Samenwerken voor meer diepgaand SCAD onderzoek

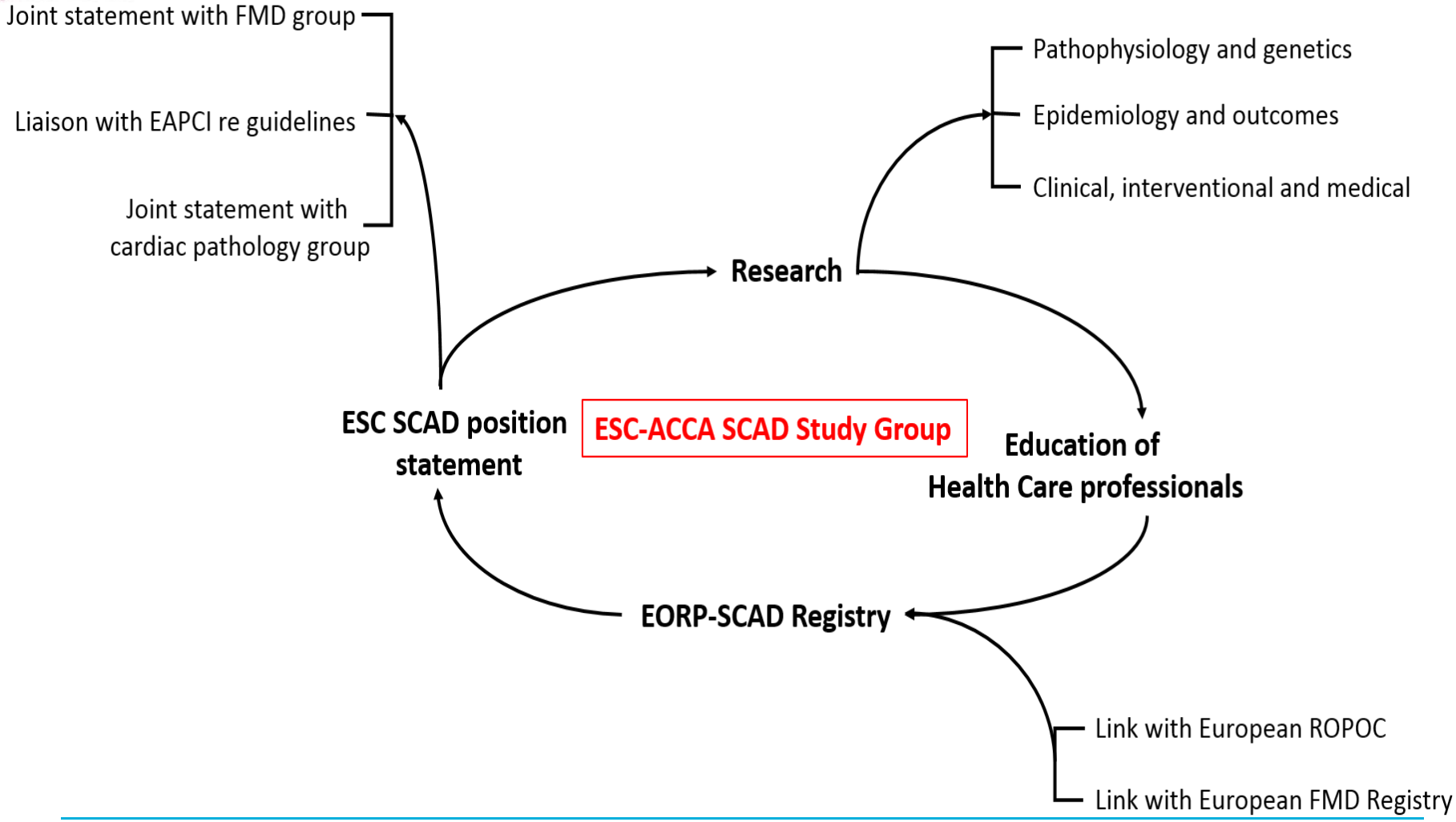

Start registratie voorjaar 2018

Acute Cardiovascular Care Association ACCA
A Registered Branch of the ESC

EUROPEAN SOCIETY OF CARDIOLOGY®

- >>500 retrospective and 500 prospective patients

Feasibility – strength in numbers:

- Holland >150
- France >200
- Switzerland ~100
- Spain ~100
- Italy ~150
- Australia ~120
- New Zealand ~100
- UK ~500

'green light'- 11th October 2017

ESC position paper in revision EHJ

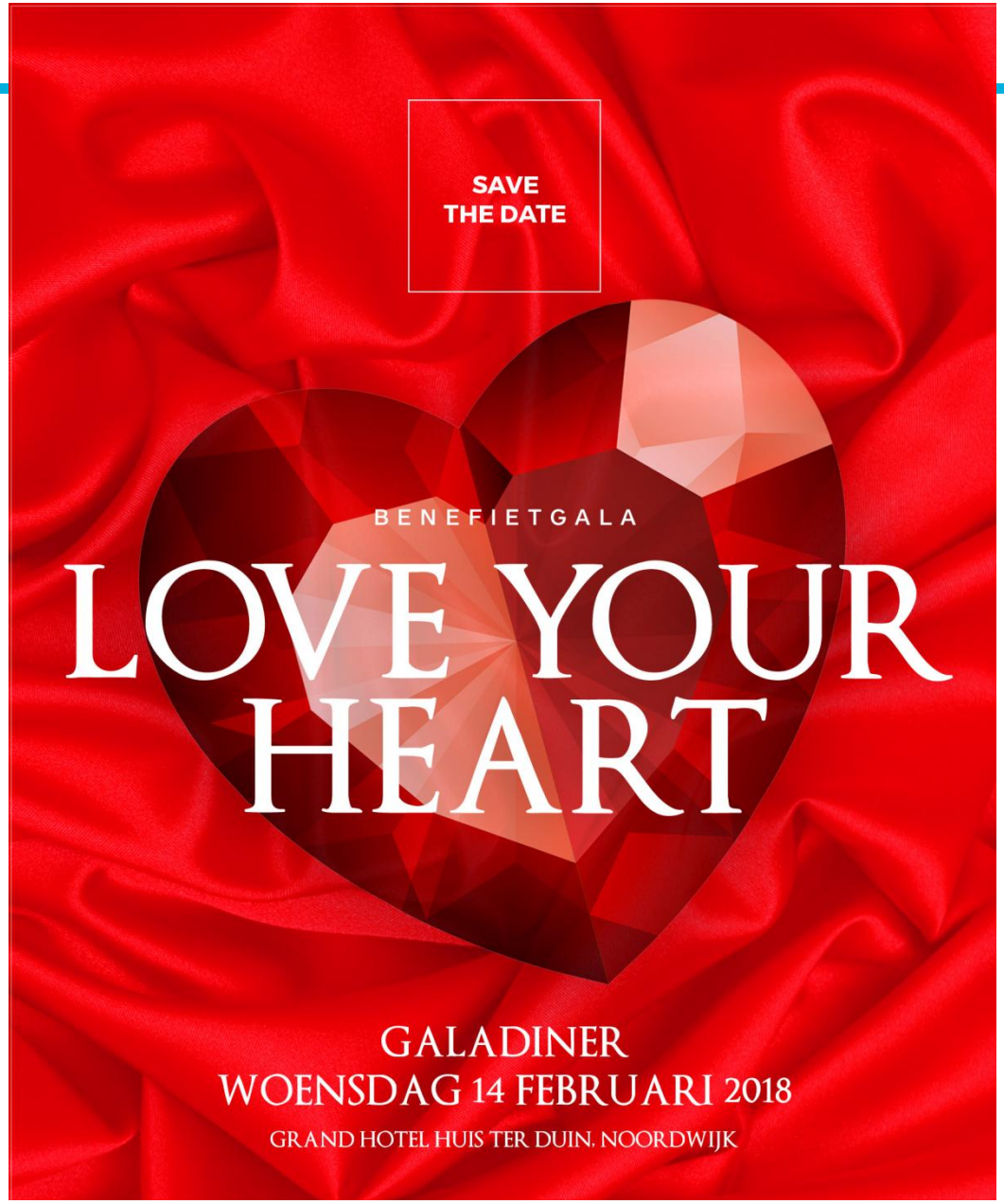

www.hartvoorvrouwen.nl eveline.kooke@radboudumc.nl